

CASE REPORT

Valerie J. Rao,¹ M.D. and Neal S. Penneys,² M.D., Ph.D.

Symmetrical Hypopigmentation of the Nipples Secondary to Trauma

REFERENCE: Rao, V. J. and Penneys, N. S., "Symmetrical Hypopigmentation of the Nipples Secondary to Trauma," *Journal of Forensic Sciences*, JFSCA, Vol. 29, No. 3, July 1984, pp. 938-940.

ABSTRACT: Deviant sexual behavior may lead to unusual skin lesions. The following is a case report of unusual trauma-related, symmetrical lesions of the nipples in a male homosexual from repeated application of bondage apparatus to his areolae and nipples.

KEYWORDS: pathology and biology, deviant sexual behavior, skin, clothespins

Case Report

A 58-year-old white man was found hanging from a closet door. According to his family, he was homosexual and practiced deviant sexual methods including bondage and masochism. While bound, he would have his partner inject various drugs, most often cocaine, into his body. In this dwelling there were several articles that he used for sexual gratification and excitement. One of these was a dog chain attached at the ends to two clothespins (Fig. 1). The clothespins were clipped to his nipples and the chain was pulled by his partner. This had been practiced for many years.

Symmetrical depigmented halos on each nipple with central ulcerations were found at autopsy (Fig. 2). The relationship of these lesions to the application of the clothespins was apparent and was confirmed by the man's sexual partner.

Death was due to suicidal hanging and there were no other injuries or pathological changes observed at the postmortem examination of the body.

Histology

The epidermis was focally ulcerated and covered by inflammatory debris. To the sides of the ulcer, there was epidermal hyperplasia. Masson-Fontana ammoniacal silver stains defined an absence of melanin in the areas of epidermal hyperplasia, but normal quantities of

Received for publication 19 Aug. 1983; revised manuscript received 22 Dec. 1983; accepted for publication 23 Dec. 1983.

¹Associate medical examiner, Dade County, Miami, FL and clinical assistant professor of pathology, University of Miami School of Medicine, Miami, FL.

²Professor of dermatology, University of Miami School of Medicine, Miami, FL.




FIG.1—Dog chain and attached clothespins used to attach to nipples.

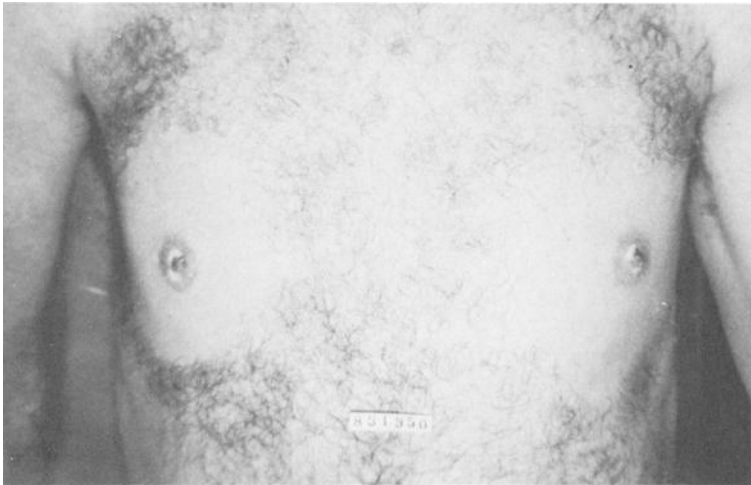


FIG. 2—Symmetrical hypopigmentation of the nipples and areolae in a male breast.

melanin were found further laterally. There was no pigment in the papillary dermis. The histologic features were not diagnostic, but suggested that the hypopigmented areas were a result of loss of melanocytes and melanin.

Discussion

This practice of nipple stimulation is fairly common among homosexual males. The nipple has certain qualities similar to those of the penis. It has been recognized as an aggressive extension of the male body, resembling the phallus, by virtue of its erectile nature, intrusive quality, and ability to discharge secretions.

Depigmentation of the nipples has not been described in the medical literature. A search through current hard-core pornographic material, however, did present the above plausible explanation.

Address requests for reprints or additional information to
Valerie J. Rao, M.D.
Dade County Medical Examiner Department
1050 N.W. 19th St.
Miami, FL 33136